

Use of TissuePatchDural™ in the closure of an iatrogenic fistula following posterior semicircular canal occlusion surgery for intractable benign paroxysmal positional vertigo

Authors: Jaswinder Singh Sandhu (1), Esmond Carr (2) and Peter Rea (2)

Location: University of Leicester Medical School (1) & Leicester Royal Infirmary (2), Leicester, UK

Citation: Sandhu JS, Carr E, Rea P. Use of TissuePatchDural™ in the closure of an iatrogenic fistula following posterior semicircular canal occlusion surgery for intractable benign paroxysmal positional vertigo. JSCR. 2010 8:8

ABSTRACT

Benign paroxysmal positional vertigo (BPPV) is a common disorder caused by the dislocation of otoconia most commonly into the posterior canal. The primary symptoms are brief episodes of head-position related vertigo which may be accompanied by nausea and disequilibrium. BPPV is usually managed conservatively with excellent results, however in a small number of cases the symptoms can become persistent and incapacitating. The most common treatment in such cases involves the surgical occlusion of the canal. This procedure carries a small risk of post operative perilymph leakage via an iatrogenic fistula.

In this paper we outline a case of a patient who developed a perilymph leak following occlusion surgery for intractable BPPV. We describe a novel surgical method that was used to close the fistula using a synthetic polymer based patch (TissuePatchDural™), which has not been applied in the field of otology previously.

INTRODUCTION

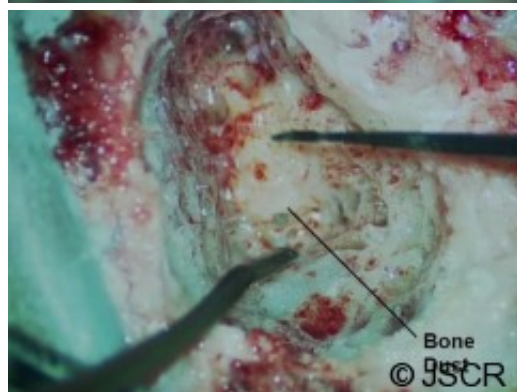
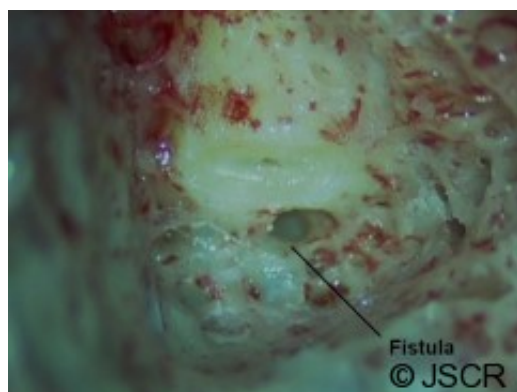
Of the inner disorders that result in vertigo the most common cause is benign paroxysmal positional vertigo (BPPV) accounting for between 17% and 40% of all vertigo cases presenting in the clinic (1-3). BPPV most commonly affects the posterior canal and the primary symptom is of brief episodes of true rotatory vertigo upon specific head movements. In most cases BPPV can be treated with particle repositioning manoeuvres (4). However in a small number of cases this does not work and surgical intervention is required. Of the surgical options available most popular is the posterior semicircular canal occlusion technique which has high success rates with low post-operative complications (5,6). The technique involves gaining access to the posterior canal via a cortical mastoidectomy and then occluding the canal preventing endolymphatic flow and thereby rendering the canal dysfunctional. Whilst complications are rare, one problem that can occur is the formation of an iatrogenic fistula. Traditionally, a combination of bone dust, fat, temporalis fascia, perichondrium and bone wax are used to repair the fistula. These materials are primarily chosen because they are easy to

apply and do not provoke a foreign body reaction. However they can fail and as result revision surgery is needed (7). In this report we describe a case of an iatrogenic fistula following posterior canal occlusion surgery in which the revision repair was done using a novel technique utilising a synthetic material (TissuePatchDural™).

CASE REPORT

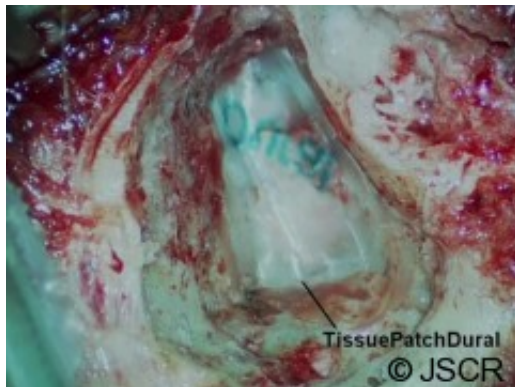
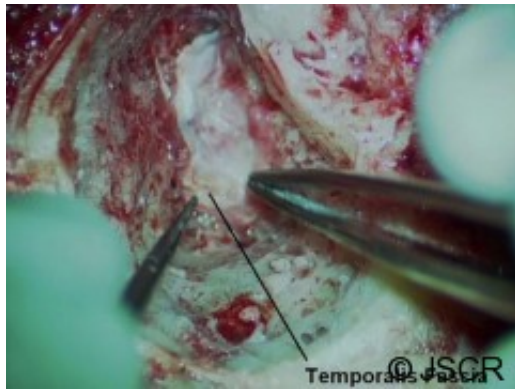
A 49 year old woman was referred to our specialist ENT balance service following a two year history of brief intermittent bouts of true rotatory vertigo coupled with continuous imbalance. There were no reported complaints of hearing loss, tinnitus, aural fullness or other otological symptoms. Magnetic resonance imaging showed no abnormalities.

Repeated Dix-Hallpike tests were positive for left sided posterior semicircular canal BPPV despite multiple particle repositioning procedures over a period of three years. As a result the option of posterior semicircular canal occlusion was agreed. The left ear was approached via a post aural incision. An extended cortical mastoidectomy was drilled into a very well aerated mastoid. The lateral semicircular canal and incus were identified and the bony labyrinth was seen suspended in the fine cancellous bone of the mastoid. This allowed exposure of the posterior semi-circular canal. This was blue lined over a long length and then cautiously opened to expose the membranes (figure 1). Bone dust and bone wax were then used to pack and occlude the canal (figure 2). A further patch of bone dust was applied over this repair and gel-foam placed on top of this.



Following surgery there was some initial imbalance but the BPPV was absent. However over the coming weeks episodes of short spinning began to occur following sudden pressure changes such as when blowing her nose or straining on the toilet. As a result a perilymph

fistula was suspected and a revision mastoidectomy planned. During the operation it was noted that over 80% of the bone graft had taken. However at the superior limit of the posterior canal a defect remained. To repair this defect the existing bone dust was carefully removed and newly harvested bone dust was reinserted into the canal. This was covered by temporalis fascia graft (figure 3) onto which a piece of TissuePatchDural™ was placed to secure the graft firmly (figure 4).



At a three month post-operative review there had been no recurrences of vertiginous symptoms and there was also improvement in overall balance. Further physical therapy exercises were given and at the time of writing this article, nine months post-operation, the patient remains symptom free.

DISCUSSION

For a small number of patients with intractable posterior canal BPPV surgical occlusion of the semicircular canal is warranted. This procedure carries a small risk of creating an iatrogenic fistula which can result in recurrence of BPPV as well as chronic imbalance. In this paper we have shown that such fistulas can be reliably repaired using TissuePatchDural™ as an adjunct to the materials already utilised by surgeons. The key advantage of using this material is that it is easy to cut to shape and size and apply. Furthermore it forms a seal quickly and acts as an excellent anchor for the bone graft to take.

TissuePatchDural™ is designed to seal and reinforce cerebrospinal fluid (CSF) leaks. We suggest that it is indicated in the repair of defects created by posterior canal occlusion surgery as well as other procedures such as intra-operative CSF leaks during mastoid surgery or endolymphatic sac repairs. As it now seems safe with both CSF and perilymph we cannot

identify specific contraindications for use in ear surgery. For these reasons we believe publicising the potential of this material may prove useful to other surgeons. To our knowledge this is the first reported case of TissuePatchDural™ used in otological surgery and in this case the resulting repair has been excellent with no complications nine months post operatively.

REFERENCES

1. [Leveque M, Labrousse M, Seidermann L, Chays A. Surgical therapy in intractable benign paroxysmal positional vertigo. Otolaryngol Head Neck Surg. 2007;136\(5\):693-8.](#)
2. [Katsarkas A. Benign paroxysmal positional vertigo \(BPPV\): idiopathic versus post-traumatic. Acta Otolaryngol 1999;119\(7\):745-9.](#)
3. [Fife TD, Iverson DJ, Lempert T, Furman JM, Baloh RW, Tusa RJ, Hain TC, Herdman S, Morrow MJ, Gronseth GS. Practice parameter: therapies for benign paroxysmal positional vertigo \(an evidence-based review\): Report of the Quality Standards Subcommittee of the American Academy of Neurology. Neurology. 2008;70\(22\):2067-74.](#)
4. [Parnes LS, McClure JA. Posterior semicircular canal occlusion for intractable benign paroxysmal positional vertigo. Ann Otol Rhinol Laryngol 1990;99:330-4.](#)
5. [Pace-Balzan A, Rutka JA. Non-ampullary plugging of the posterior semicircular canal for benign paroxysmal positional vertigo. J Laryngol Otol 1991;105:901-6.](#)
6. [Seltzer S, McCabe BF. Perilymph fistula: the Iowa experience. Laryngoscope 1986;96:37-38.](#)
7. [Rizvi SS, Gauthier MG. Unexpected complication of posterior canal occlusion surgery for benign paroxysmal positional vertigo. Otol Neurotol 2002;23:938-40.](#)