

Use of Tissue Patch sealant film for treating chylous leak after major neck surgery

Leo Cheng, Stuart Heaton, Gary Parker and all volunteer crew members

Oral & Maxillofacial, Head & Neck Surgery, Barts and The London NHS Trust, Homerton University Hospital, and Africa Mercy, The Mercy Ships

Barts and The London **NHS**
NHS Trust

Homerton University Hospital **NHS**
NHS Foundation Trust



Introduction

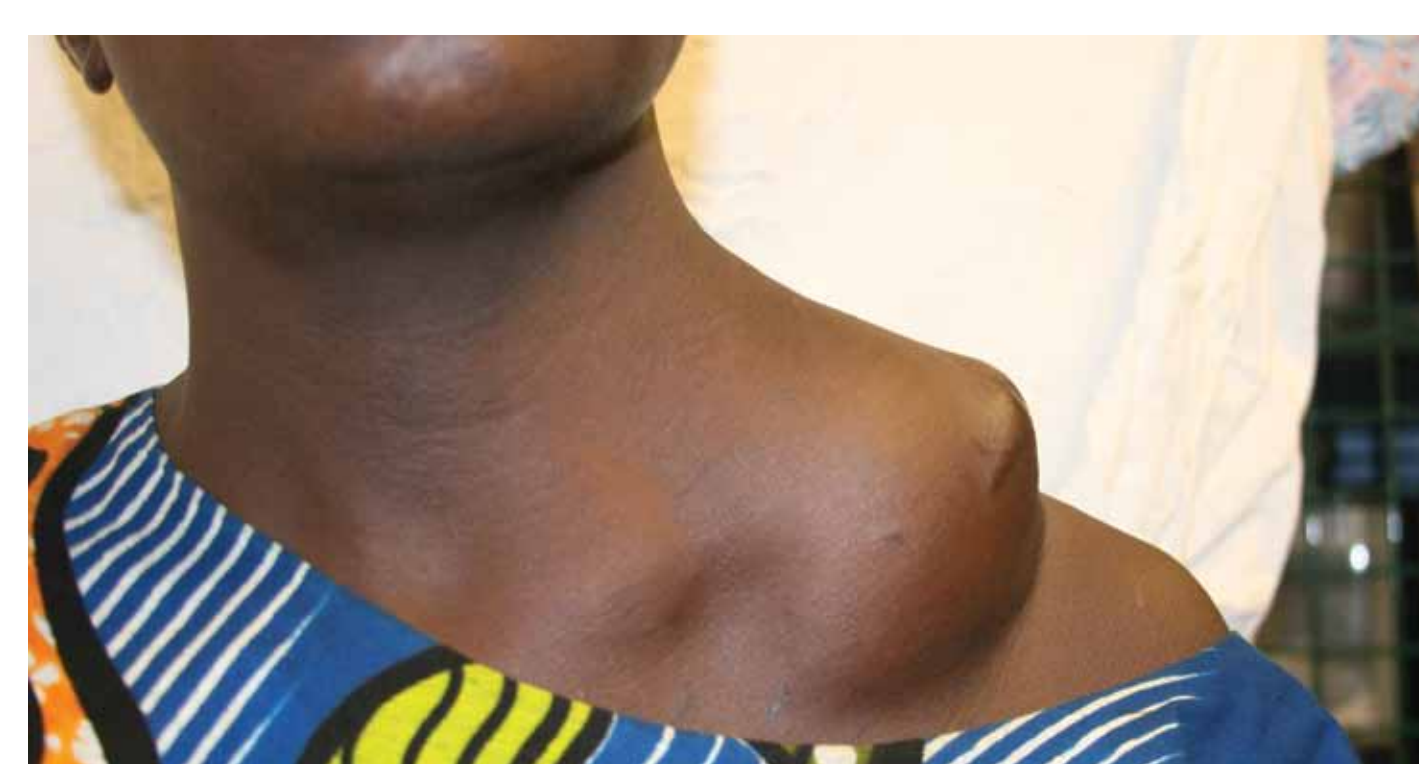

Chylous fistula is a rare but well recognized and serious complication following major neck surgery. Various medical management has been advocated to reduce chylous flow for low volume leaks and to maintain nutritional status. However surgical exploration is often required after failed medical management in high fistula output. We report the use of Tissue Patch sealant film on 2 patients as an adjunct to ensure an effective seal to potential sources of chylous leak.

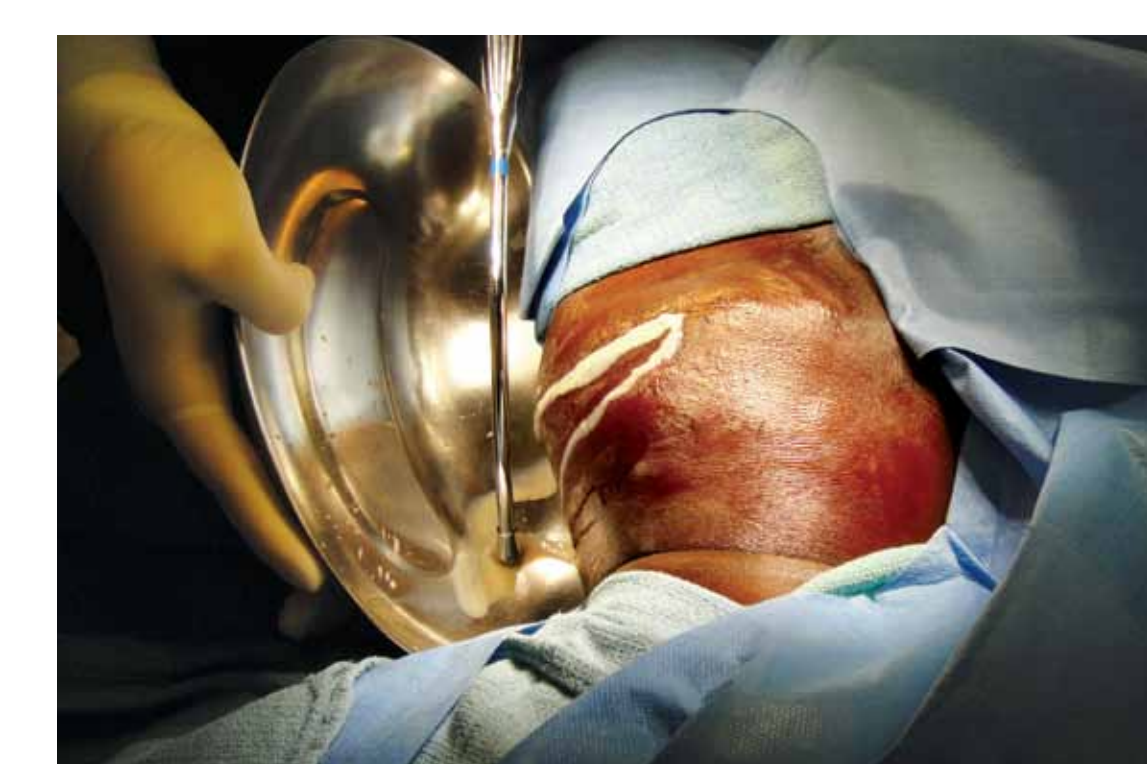Case Report 1

A 40 year old African lady presented to the Mercy Ships in Benin, West Africa with a 12 year history of a non-tender slow growing left supraclavicular mass. Ultrasound and Computed Tomography (CT) showed a large soft tissue mass separated from pleura suggestive of a teratoma. Fine needle aspiration cytology was non-conclusive. She underwent excision of extensive teratoma with preservation of brachial plexus and accessory nerve with no chylous leak. During extubation, the patient developed a small haematoma and it was evacuated on the same day. Her postoperative course was complicated by a slowly enlarging left lower neck swelling. Surgical exploration of the neck revealed a chylous

collection of over 1 liter of blood-stained chyle. Chylous leaks were identified from 3 sources, 2 at inferior and one at mid cervical regions. These areas of leakage were ligated and oversewn with surrounding soft tissue. A 50 x 50 mm Tissue Patch Dural was cut into 2 small pieces and applied over 2 inferior leaks. The patch provided an effective water-tight seal with no chylous leak on Valsalva maneuver. The patient developed a firm supraclavicular swelling and re-exploration of the neck reviewed leakage of chyle from a dilated mid cervical lymphatic channel. The other 2 previous sources of leakage at the base of the supraclavicular cavity sealed by Tissue Patch Dural, remained dry with no leak.



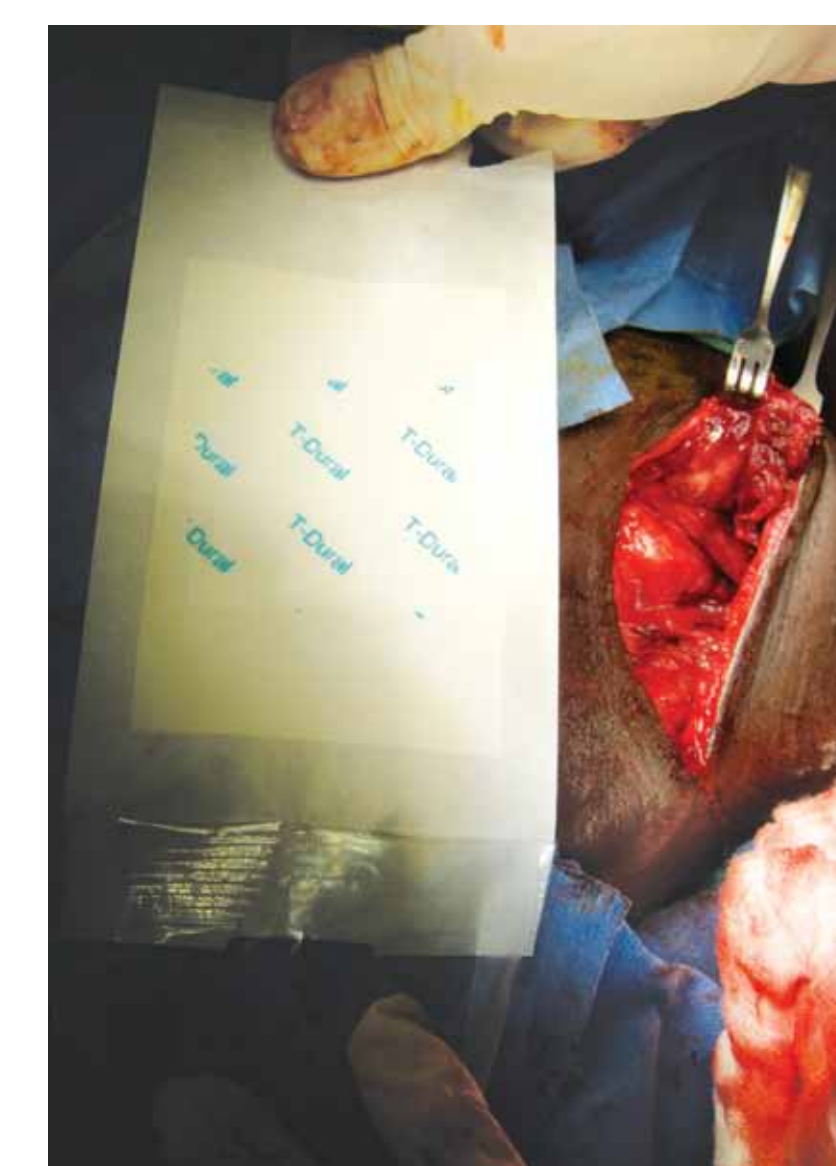
1. Large supraclavicular teratoma



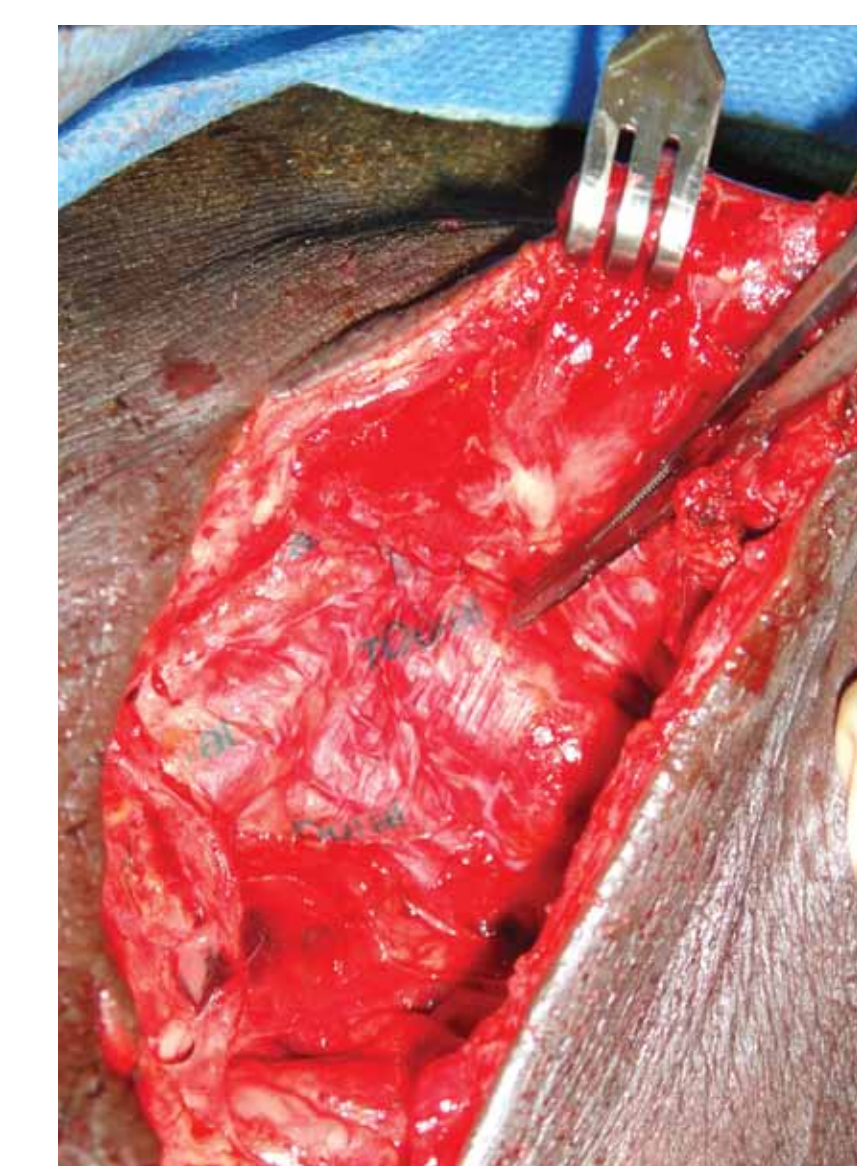
2. Chylous collection of creamy lymphatic drainage after an initial incision



3. Initial drainage of chylous leak



4. Tissue Dural was used to seal chylous leak after muscle flap repair

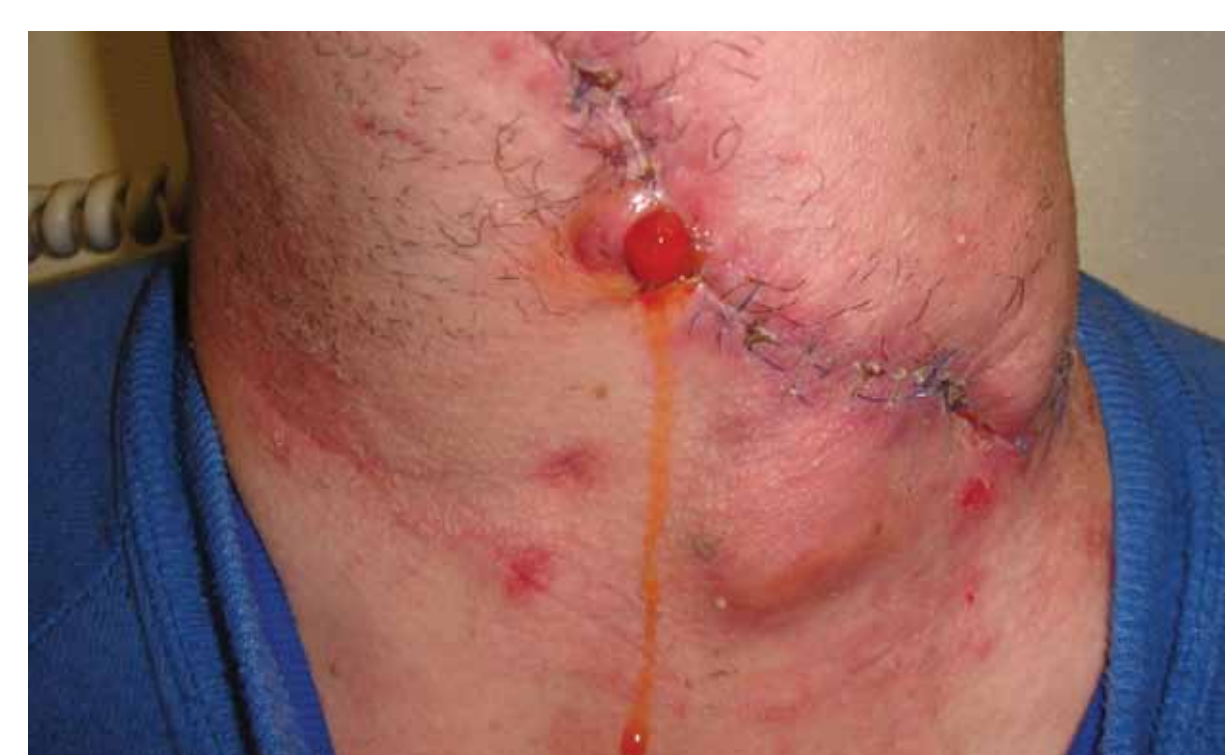

5. Methylene mark of Tissue Dural can be seen

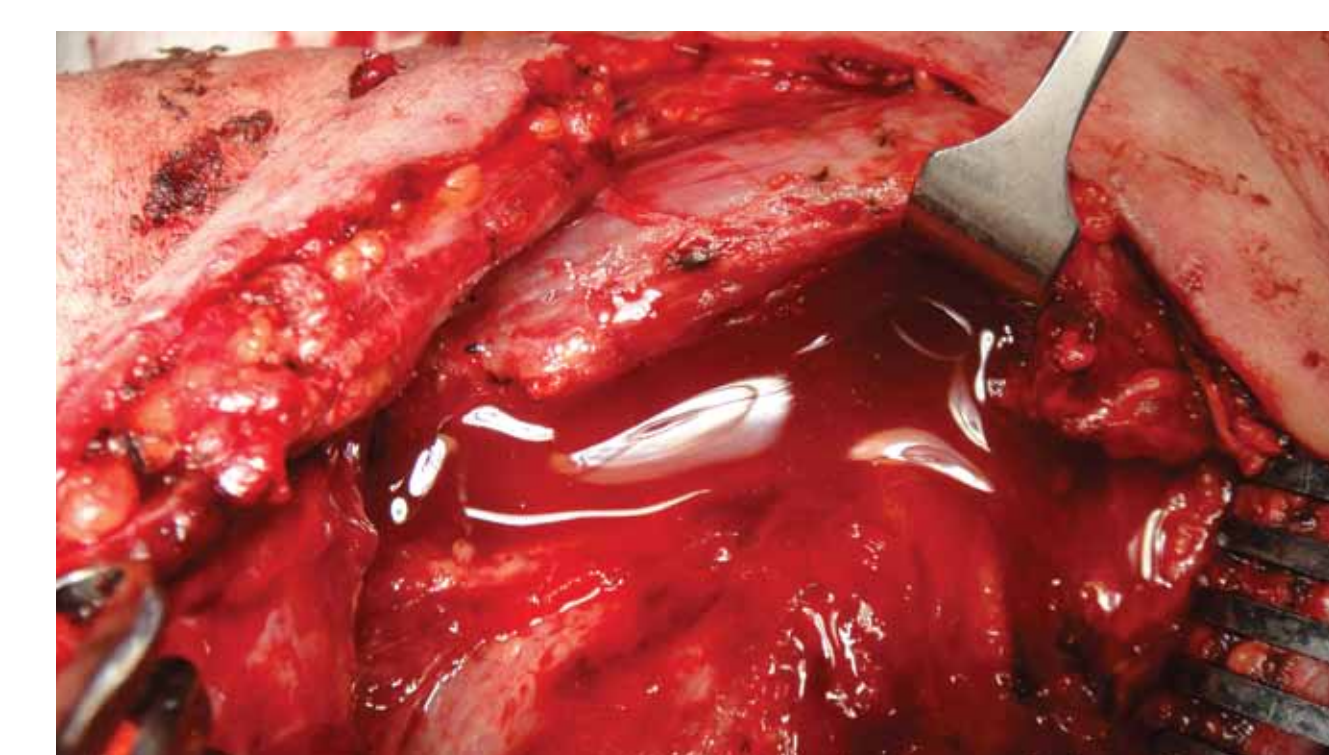Case Report 2

A 52 year old Caucasian gentleman with a 6 month history of left neck swelling attended our neck lump clinic and ultrasound guided FNAC showed metastatic carcinoma. MRI and PET/CT did not detect a possible primary source. Panendoscopy, tonsillectomy and multiple biopsies revealed left tonsillar carcinoma. He then underwent left total neck dissection. No chylous leak was noted during operation. On the 4th postoperative day, chylous fluid

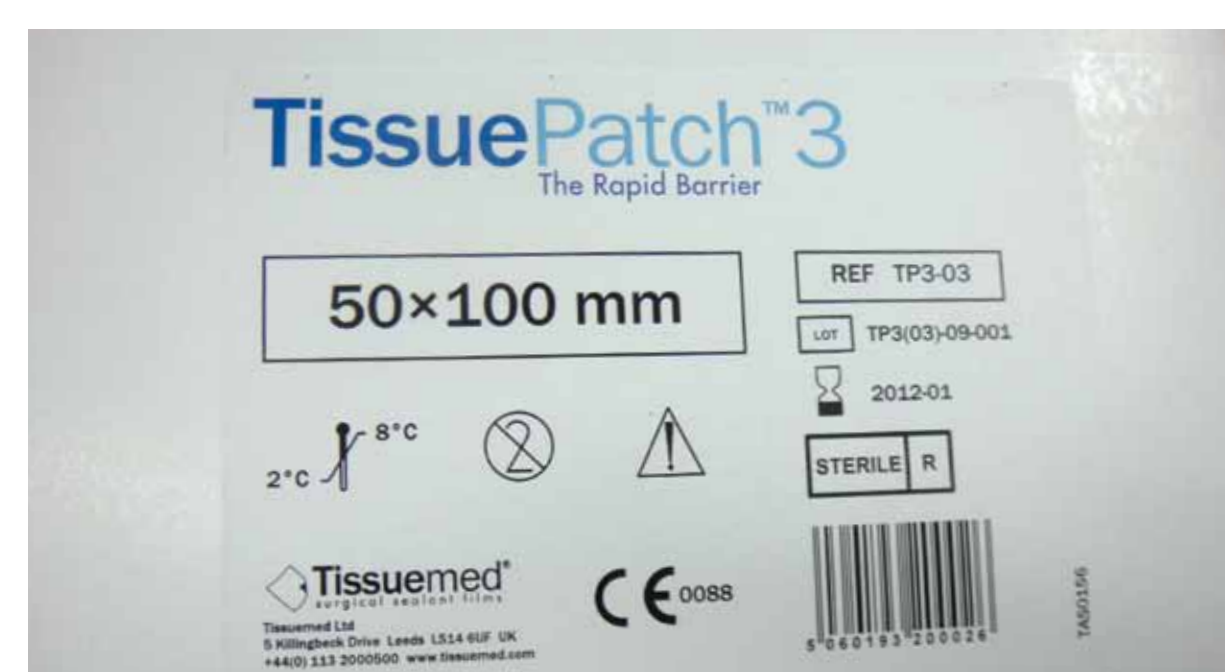was seen in the vacuum suction drain. The drain was removed and a pressure bandage was applied. Chylous leak continued with more than 300ml per day. His left neck was explored and an extensive collection of chyle was evacuated. The chylous leak was identified, oversewn and Tissue Patch 3 was applied over the soft tissue. No further leak was identified with Valsalva maneuver. He remained well and received postoperative chemoradiotherapy.



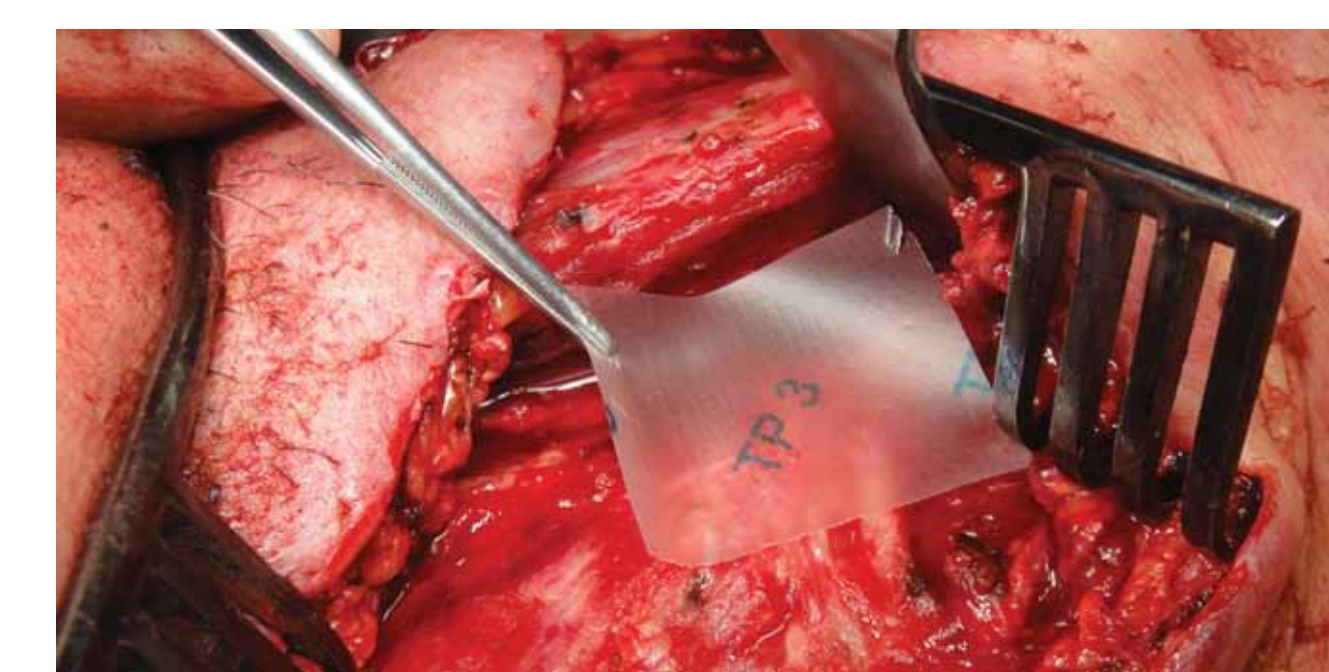1. Chylous leak after neck dissection



2. Re-exploration of neck revealed serous and chylous leak



3. Tissue Patch 3



4. A piece of Tissue Patch 3 acted as an adjunct for effective seal

Discussion

The Tissue Patch sealant film was easy to apply and quick due to its adhesiveness by creating bonding with the underlying soft tissue bed. It conforms well to the contour of the soft tissue bed. The film conforms well with the irregular surfaces of the soft tissue and potential sources of chylous leak. As it is a biodegradable material, it is therefore safe to use leaving no foreign body over the neo-tissue.

Conclusion

Chylous fistula is rare and surgical management is often required for high output fistula after major neck surgery. Tissue Patch sealant film has been found to be a useful adjunct to ensure an effective seal to the potential sources of chylous leak.