

# ADHESIVE SEALANT BIOMATERIALS

Clinical Series

Leo Cheng

St Bartholomew's, the Royal London, & Homerton University Hospitals, London, and the Mercy Ships

## Use of TissuePatch™ following Thyroidectomy

### Pre-operative status

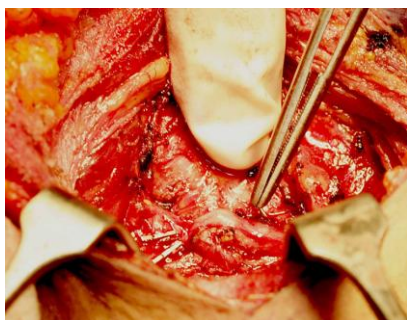
A 27 year old male presented with an enlarging neck swelling and compressive symptoms with intermittent dysphagia and dyspnoea from his right retrosternal goitre.

### Surgical procedure

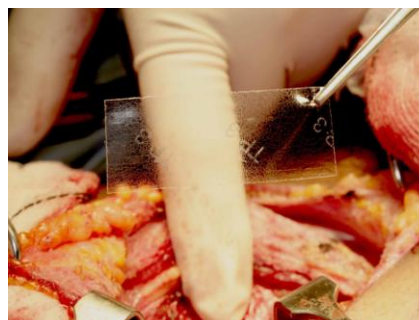A standard lower neck collar incision was made to gain access to the goitre after bilateral ultrasound guided cervical plexus block with long-acting levobupivacaine. A sizeable right thyroid gland was removed using ultrasound treatment delivered by the HARMONIC FOCUS® Curved Shears. Laryngeal nerve stimulator was used to aid the identification of the recurrent laryngeal nerve which was preserved. A parathyroid gland was also identified. Tissue Patch 3 and a Redivac drain were inserted.

### Treatment with TissuePatch3™

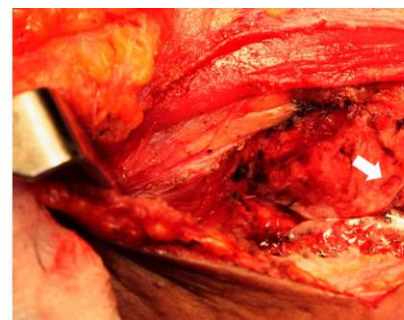
A 100 × 100 mm TissuePatch3 was cut into 4 strips, each typically 20-25mm wide. These sections were used to line the thyroid bed and in particular covered the recurrent laryngeal nerve, the superior thyroid region, the parathyroid gland, the trachea and the sternomastoid muscle. Tissues within the thyroid cavity were dried and the patch conformed to the contour of the tissues. The patch adhered to the tissues after gentle pressure with a moist saline gauze for a period of 30-60 seconds. These treatments provided an effective fluid-tight seal and also protection to the recurrent laryngeal nerve and parathyroid gland.



Tissue bed following removal of right thyroid.



Strip of TissuePatch3 prior to application.



Appearance following application. Arrow identifies surface marking logo.

### Post-Operative Recovery

The patient required minimal postoperative analgesia and had 15 ml of blood in the Redivac drain in 24 hours. His voice was normal with normal serum calcium. He was discharged on the following day. There was no complication in his outpatient review appointments.

### Summary and Surgical Opinion

Post operative blood loss is a well recognised complication following thyroidectomy, with up to 100ml of fluid collected following this surgery. In this procedure TissuePatch3 was used as an adjunct to ensure effective seal to the potential sources of blood and other fluid leakage. TissuePatch3 was easy and quick to apply, bonding rapidly to a variety of tissues within the thyroid bed. The device conformed well to the tissues and provided an effective watertight seal eliminating post-operative blood loss. Moreover, TissuePatch3 also provide protection of the recurrent laryngeal nerve and parathyroid gland at the thyroid bed from the vacuum suction drain.

HARMONIC FOCUS® is a registered trademark of the Johnson & Johnson Corporation.

Tissuemed Ltd. • 5 Killingbeck Drive • Leeds • LS14 6UK • United Kingdom

[www.tissuemed.com](http://www.tissuemed.com) • Tel +44(0)1132000500 • Fax +44(0)1132407343 • ©Tissuemed 2011

March 11 CS63/01