

Use of TissuePatch3 sealant film in reducing vascular leak after thyroid surgery

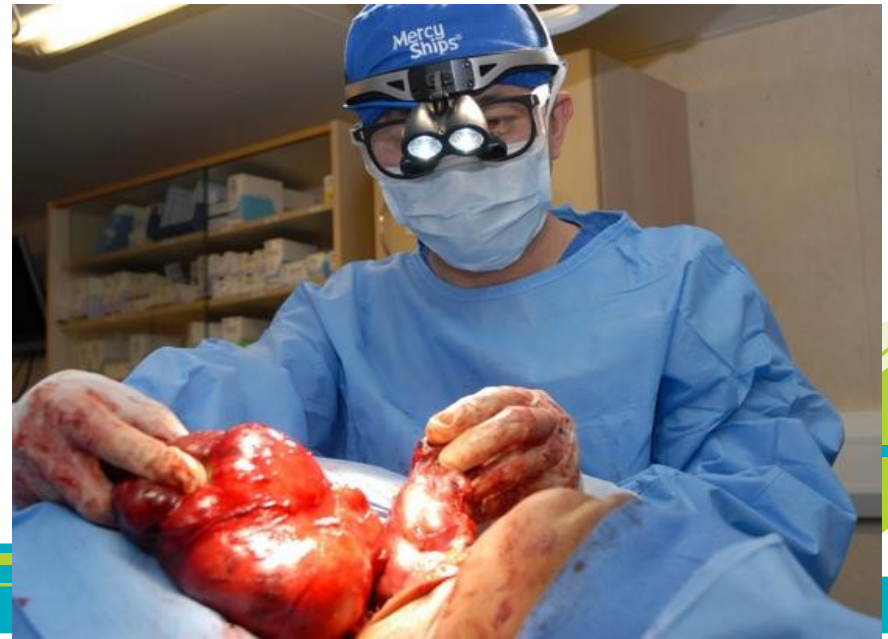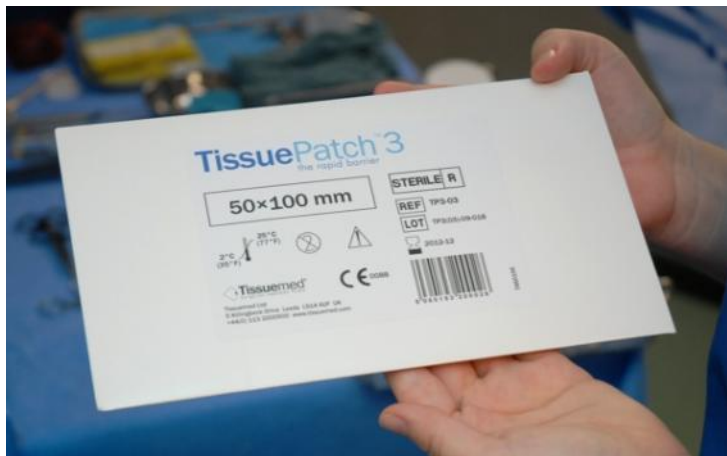
L Cheng

**Ali E, Qureshi R,
Qureshi I, Qureshi
A, Anderson J,
Medici F,
Emery M**

**Endocrinology and
Oral and Maxillo-Facial Surgery**

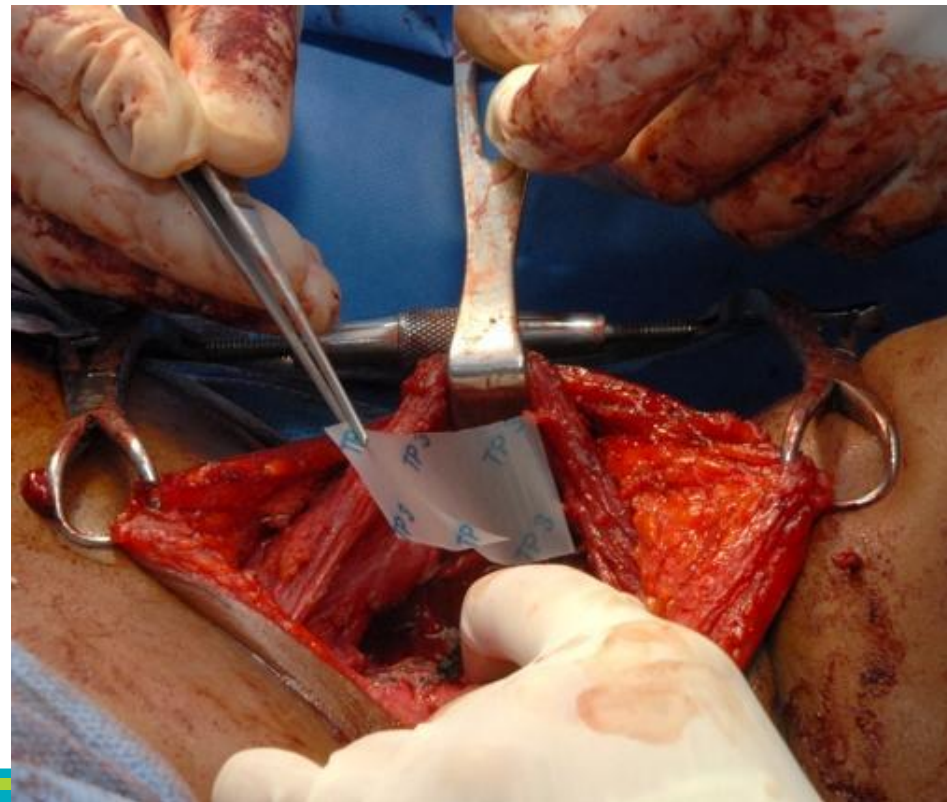
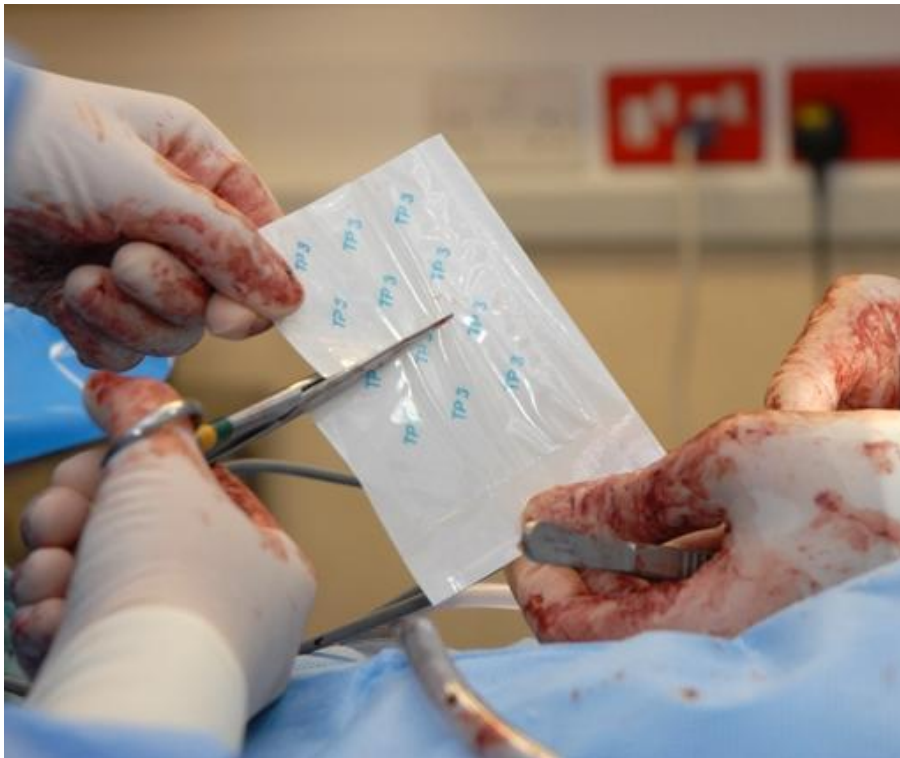Introduction

- Standard method of closure of exposed thyroid tissue with transfixed continuous sutures and using oxidized cellulose (Surgicel™) to line the thyroid beds have been well established to prevent post-thyroidectomy haemorrhage.
- TissuePatch3 (TP3) is a self-adhesive, absorbable surgical sealant and barrier which have been used to seal and reinforce against leakage in neurosurgery and thoracic surgery.
- We therefore investigated the feasibility of TP3 sealant film after thyroid surgery as an adjunct to ensure effective sealing of potential sources of vascular leak.



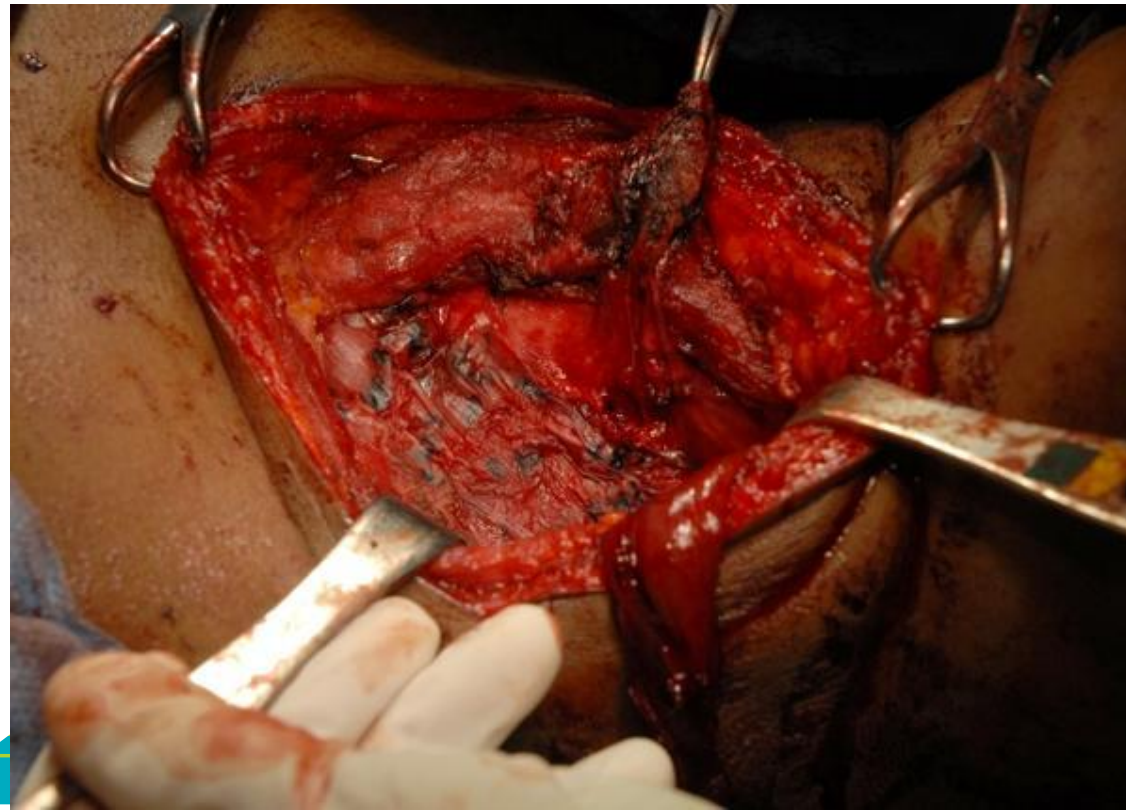
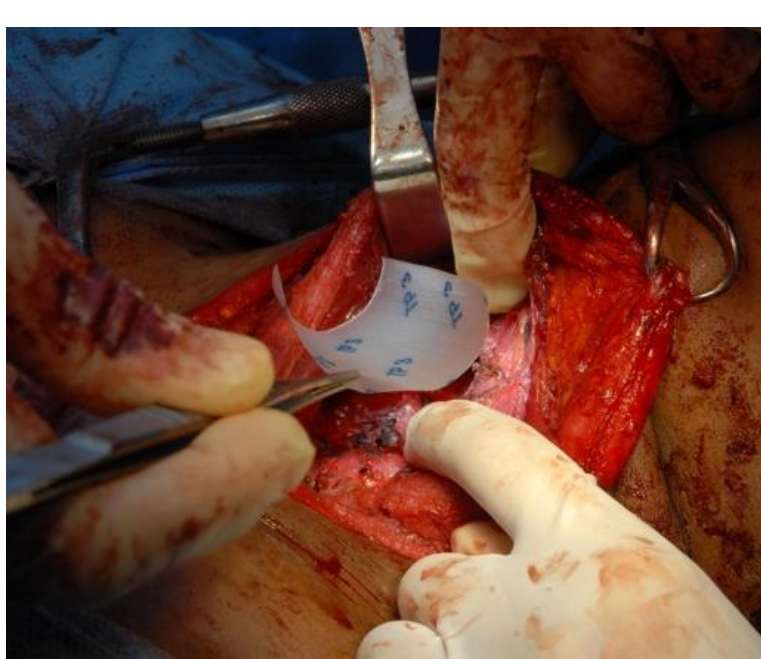Material and Methods

- 28 patients underwent total or hemithyroidectomy had TP3 sealant film applied to thyroid bed and cut end of thyroid isthmus in hemithyroidectomy
- 34 thyroidectomy patients had no TP3 and they acted as control.
- Drainage and bed stay after surgery were recorded.



Results

- Average bed stay for patients without TP3 was 3 days (range 1-8) and average drainage of 60ml (range 10-380).
- For TP3 patients, average bed stay was 2 days (range 1-5) and average drainage of 28ml (range 5-100).
- No patients had postoperative haemorrhage or recurrent laryngeal nerve interference.



Discussion

- Haemorrhage and haematoma after thyroid surgery is rare but can be fatal.
- The TP3 sealant film is easy and quick to apply.
- It is adhesive by virtue of forming a bond with the underlying soft tissue bed.
- It is biodegradable leaving minimal foreign body over the neo-tissue.

Conclusion

We have found that TissuePatch3 sealant film can be used as an adjunct to ensure an effective seal to the potential sources of oozing or bleeding from cut ends of thyroid tissue and thyroid bed.

